

Hydatids – you, too, can be affected

Stuart King

Former Senior Field Veterinary Officer

Dr Gareth Hutchinson

Research Officer, Health Science, Strategic Alliances & Evaluation, Menangle

Introduction

Hydatid disease (also known as hydatidosis or echinococcosis) is caused by a tapeworm which infects dogs, dingoes and foxes. At its intermediate stage, it forms cysts in the internal organs, especially livers and lungs, of a number of animals, including humans. In humans, the disease is so serious that it requires surgery for treatment. Hydatid disease also causes losses in livestock with the downgrading of edible meat by-products because of the presence of the hydatid cysts.

Control of hydatid disease involves the elimination of the hydatid tapeworm from dogs. By carrying out the recommended control measures, the infection of dogs with the tapeworm can be prevented, and the spread of the disease to other animals, including humans, reduced.

With better control of hydatid disease in domestic livestock and dogs, it is the hydatid cycle that occurs in wildlife which is becoming relatively more important as a threat to human health.

The hydatid tapeworm

In Australia, cystic hydatid disease (CHD) is caused by the unilocular hydatid tapeworm, *Echinococcus granulosus* (see Figure 1), which infects primarily the dog and the dingo. (The term 'unilocular' refers to the fact that the cysts are characterised as having only one bladder.) There have been reports of infection in the fox, but, because of its feeding habits and the fact that it carries fewer worms than dogs, the fox does not pose as serious a threat to humans or livestock.

The multilocular (multiple-cyst-forming) tapeworm *Echinococcus multilocularis*, which causes very aggressive alveolar hydatid disease (AHD) where

the vesicles resemble lung pockets, is found in Japan, Alaska and parts of Europe, but fortunately does not occur in Australia or New Zealand.

The *E. granulosus* tapeworm consists of 3–4 segments (proglottids) and is only about 6 mm long when fully grown. Because it is small, thousands of these tapeworms can inhabit the intestine of a dog without causing any ill effects, and are usually very difficult to see in gut contents because they resemble intestinal villi (the finger-like folding of the gut lining).

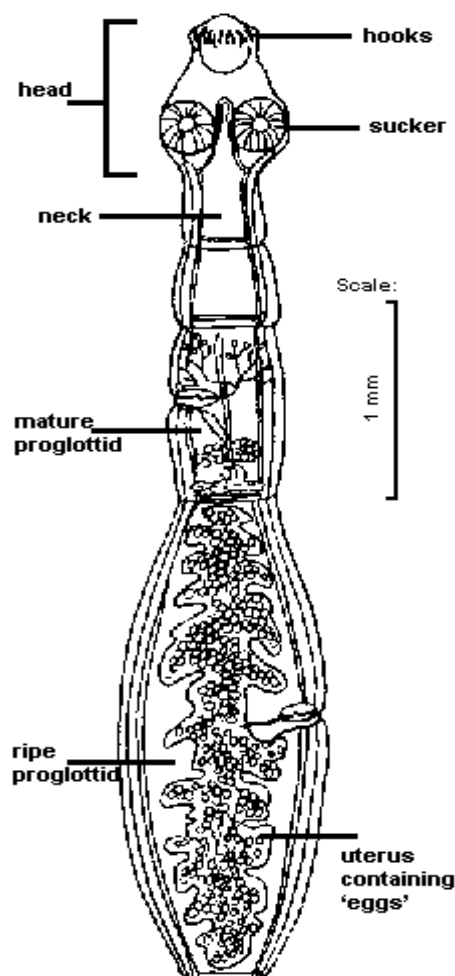


Figure 1. The hydatid tapeworm *Echinococcus granulosus*



A dog, dingo or fox can become infected with these tapeworms only by eating tapeworm heads, called **protoscolices**, contained in cysts or in food contaminated with cyst fluid that contains protoscolices. (Protoscolices are sometimes called 'hydatid sand' because of their gritty feel when cysts are sliced open.)

When swallowed by a dog, the tapeworm head embeds in the lining of the dog's intestine and begins to grow, taking about 6 weeks to reach maturity. When mature, the last segment of the tapeworm may contain a thousand eggs. A segment containing eggs is shed by the tapeworm every 14 days. A new segment, filled with eggs, then develops to take its place.

Hydatid eggs in the life cycle

After being shed in faeces, the segments rupture, scattering the eggs which can be moved about by wind and water. They are highly resistant to weathering and can remain infective for several months, particularly in cool climates. Contamination of the dog's kennel area, playgrounds, vegetable gardens, pastures and the dog's coat can easily occur (see Figure 2).

The eggs cannot continue their life cycle until swallowed by a susceptible animal – sheep, pigs, goats, camels, deer, cattle, kangaroos and humans. When the egg is swallowed, it hatches to release a small, hooked embryo which burrows its way through the gut wall. It is then picked up by the

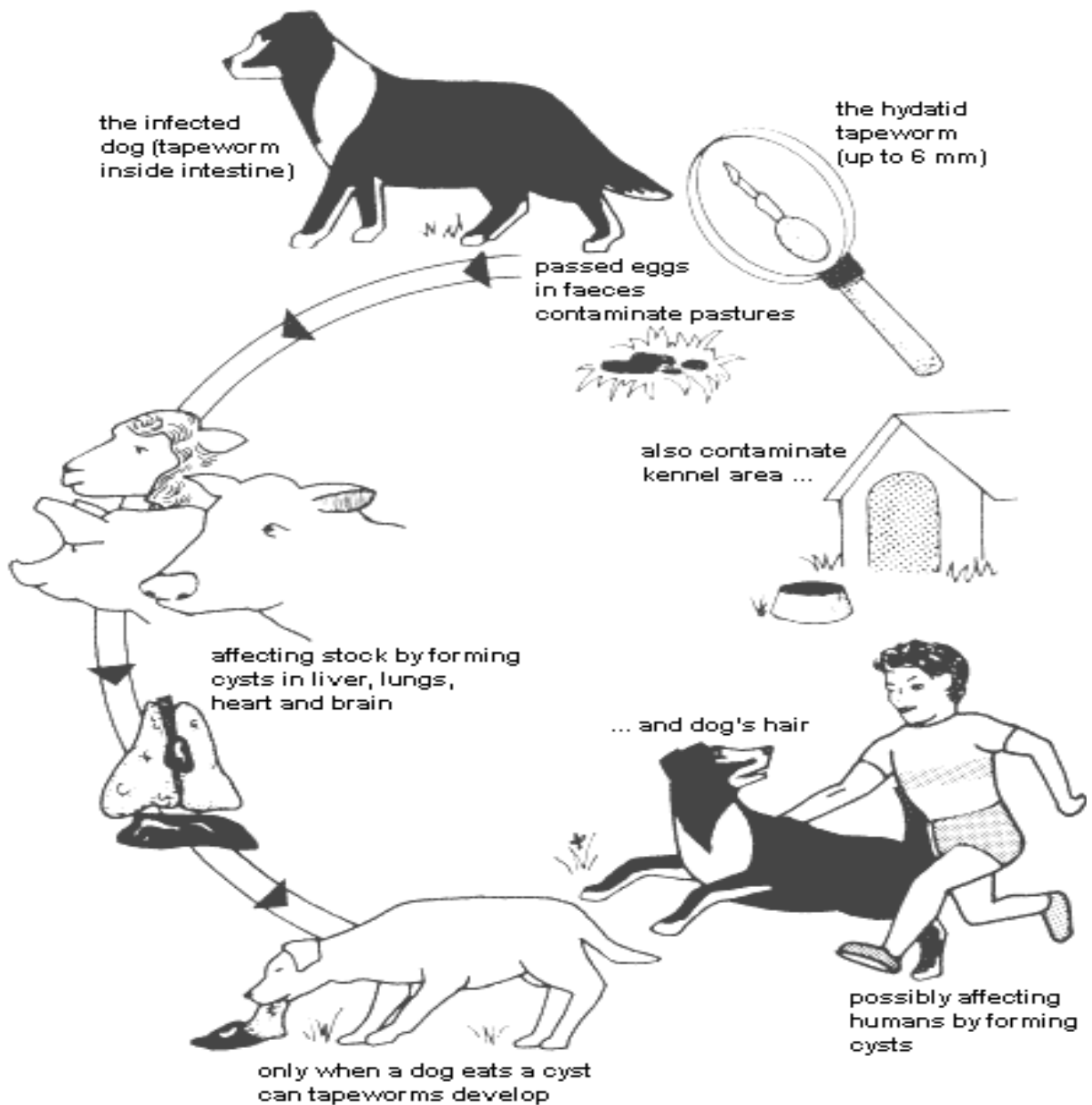


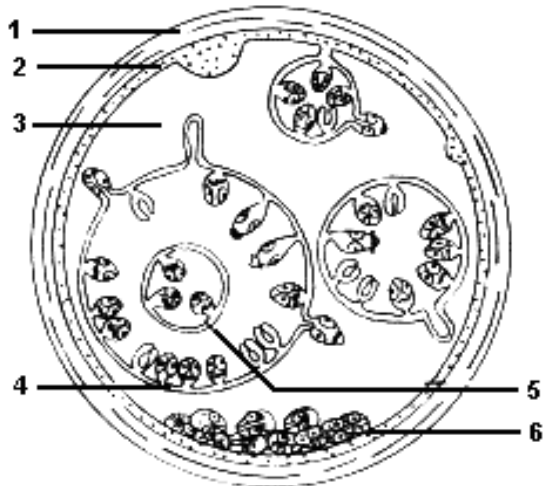Figure 2. The hydatid life cycle. Each time an infected dog passes faeces, thousands of eggs may be released.

bloodstream and transported to the liver, lungs or, less frequently, to another organ such as the brain. Once lodged, the embryo develops into a hydatid cyst, which is a fluid-filled sac.

The hydatid cyst

The outer layers of the cyst (see Figure 3) consist of fibrous tissue laid down by the host and have a characteristic laminated appearance. The cyst is lined by a germinal membrane from which brood capsules grow. Within the brood capsules, the next generation of tapeworm heads forms. Each capsule may contain up to 40 heads or protoscolices (see photo of protoscolices in Figure 4).

Brood capsules which become detached from the germinal membrane and float free within the fluid are referred to as daughter cysts. Brood capsules release the tapeworm heads ('hydatid sand'). If a cyst ruptures within a host, the brood capsules can form new cysts, called secondary cysts.



1. Fibrous tissue of host
2. Germinal membrane of cyst
3. Hydatid fluid
4. 'Daughter' cyst or brood capsule
5. 'Grand-daughter' cyst
6. Hydatid 'sand' (protoscolices)

Figure 3. *Echinococcus granulosus* cyst

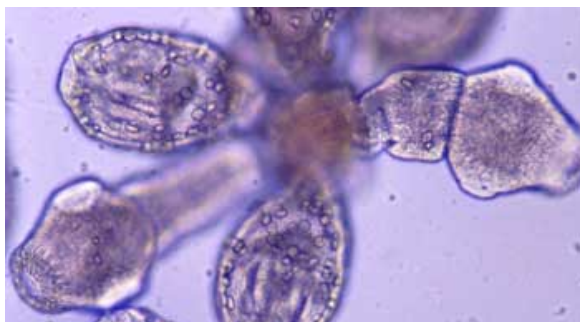


Figure 4. Photograph of protoscolices from a hydatid brood capsule. Photo: Gareth Hutchinson

The speed with which the cyst grows varies with the species of the host. In sheep, for example, it takes about 3 months for a cyst to grow to 4–5 mm in diameter, and another 3 months for it to reach 20 mm in diameter.

In other animals, cysts with diameter 5–20 cm, or larger, can develop. A mature, fertile hydatid cyst can contain up to 100 000 brood capsules, and each of these may contain up to 40 tapeworm heads – a total of 4 million tapeworm heads. Not all hydatid cysts are fertile.

As the animal gets older, some of the cysts die and form scars. Often, dead cysts become filled with caseous (cheesy) material, or they become calcified, but the outer laminated layers can still be distinguished microscopically.

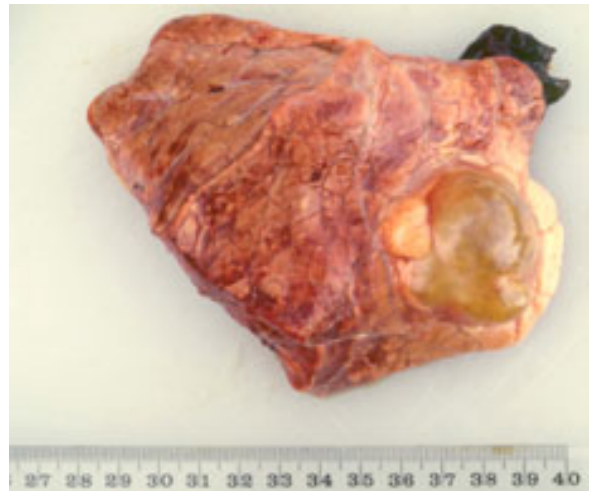

Figure 5. Photograph of fluid-filled hydatid cyst in bovine lung. Photo: Gareth Hutchinson

Animals affected by hydatids in Australia

The adult hydatid tapeworm can infect the dog (including wild dogs and feral crosses with dingoes), dingo and fox.

Larval cysts, resulting from ingesting hydatid eggs released from an infected dog, dingo or fox, can develop in humans, sheep, cattle, goats, deer, horses, pigs, camels, kangaroos, wallabies and wombats. In Australia, hydatid cysts have not been reported in alpacas, and have only rarely been reported in horses, although they are common in horses in the UK. No reports of hydatid cysts in water buffalo are known from Australia. The percentage of fertile cysts varies with the species and age of the host animal.

- In Australia, most fertile cysts are found in sheep or certain species of macropod marsupials (kangaroos and wallabies). The main source of domestic transmission of infective cysts in Australia is from sheep to dogs (the domestic cycle – see below).

- Most cysts in cattle, feral pigs or other hosts in Australia are not infective.

Hydatid life cycles in Australia – how the infection spreads

Domestic cycle

Dogs, dingoes or foxes can become infected with tapeworm only if they swallow a tapeworm head. This comes from either fertile cysts contained in the liver, lungs or other organs (offal) they eat or by eating meat or blood that was contaminated by cyst fluid when the animal was killed. (See Figure 6.)

Wildlife or sylvatic cycle

Dingoes and wild dogs usually become infected by eating kangaroos or wallabies carrying cysts. The eggs shed in the faeces of these dogs sometimes contaminate areas grazed by sheep or cattle, causing them to be infected with cysts. In comparison with the dingoes and wild dogs, very few foxes are likely to be infected and their tapeworm burdens are usually low (<50 worms), so their contamination of pastures will be insignificant in the overall disease pattern. (See Figure 7.)

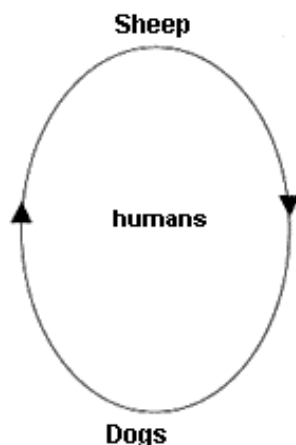


Figure 6. Hydatid tapeworm domestic cycle

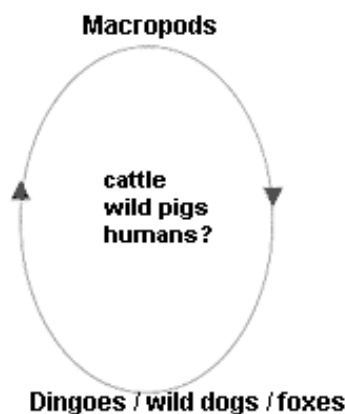


Figure 7. Hydatid tapeworm sylvatic (wildlife) cycle

At one time it was thought that the strains in the domestic life cycle and the sylvatic life cycle were distinct, but it now appears that they are genetically the same.

Cysts in accidental intermediate hosts, such as feral pigs, cattle and humans, are usually not fertile and/or not involved in the maintenance of the life cycle (i.e. a 'dead end' host).

Hydatid strains

Field and laboratory studies over almost 50 years have revealed a wide variety of morphological, biological and biochemical differences in *Echinococcus granulosus*. Variations have been reported in:

- fertility of cysts;
- rates of development in the dog (this is important as it can affect timing of treatment for adult tapeworms before they have the opportunity to pass eggs in faeces);
- rostellar hook size;

Such worms have been recognised as 'strains', and even as separate species. See Thompson & McManus 2002 for details and discussion on the case for separate *Echinococcus* species in the horse (*E. equinus*) and cattle (*E. ortleppi*).

Biochemical and recently genetic (molecular biology) characterisation of different isolates/strains has revealed at least nine genetically distinct strains (see Table 1).

- In Australia, only two genotypes, G1 (common sheep strain) and G2 (Tasmanian sheep strain), have been recorded, but on the Australian mainland, only G1 occurs. The current status of G2 in Australia is uncertain since it has never been reported on the mainland (DJ Jenkins, pers. comm., 2005), and the success of the Tasmanian eradication program is likely to have made this strain extinct in its place of origin. Cattle in Australia are frequently infected with hydatid cysts, but in all cases these are the common sheep strain (G1) and the cysts are usually not fertile.
- In overseas countries, where there are other genetic strains of hydatids present, 94% of hydatid cysts in sheep, 88% in pigs, 70% in goats, and 10%–20% in cattle, may be fertile and able to infect dogs.

Cattle case study

Cattle may be infected with a number of strains (although, in Australia, only with the G1 common sheep strain).

Table 1. Strains of hydatids

	Genotype (strain)	Other hosts	Location in Australia	Other countries
Found in Australia	G1 (common sheep strain)	sheep	mainland	UK, Europe, Africa, Middle East
		cattle	mainland	UK, Europe, Africa, Middle East, China
		human	mainland and (formerly) Tas.	Europe, Middle East, Africa, China, South America
		buffalo	NR	India
		pig (domestic)	NR	China
		pig (feral)	mainland	NP
		camel (incl. alpaca)	?	China
		kangaroo	mainland	NP
		wallaby	mainland	NP
		dog	mainland & (formerly) Tas.	Africa
		dingo	mainland	NP
	G2 (Tasmanian sheep strain)	sheep	?Tas.	Argentina
		human	NR	Argentina
Not found in Australia	G3 (buffalo strain?)	buffalo		India
	G4 (horse strain)	horse, donkey		UK, Europe
	G5 (cattle strain)	cattle, sheep, buffalo, human		Europe, India, Nepal, Brazil
	G6 (camel strain)	camel, cattle, human, sheep, goat		East Africa, Middle East, China
	G7 (pig strain)	pig, wild boar, beaver, cattle, human		Eastern Europe, Argentina
	G8 (cervid strain)	moose, human		USA
	G9?	pig, human		Poland

NR = not recorded, NP = not present, ? = current status not certain. Adapted from McManus & Thompson 2003

In Europe there is a well characterised 'Swiss' cattle strain (G5), also found in India, Nepal and South America:

- This strain has precocious development in the dog, taking only 5 weeks to produce eggs (i.e. 5 weeks to patency).
- It has a predilection for the lungs for cyst development.
- The cysts are frequently fertile.
- This strain can also infect humans.

Camel strain (G6) is reported in cattle in Iran (Fasihi Harandi et al. 2002).

Cysts caused by other larval tapeworms

Hydatid cysts need to be distinguished from **cysts caused by other larval tapeworms** found in cattle and sheep: see Table 2, below.

Hydatid disease in humans

Hydatid disease in humans can result only from swallowing eggs released from an infected dog, dingo or fox. Early in the 20th century in some areas of New South Wales, particularly the Southern and Northern Tablelands, infection in humans was a common problem and death as a result of the disease was all too frequent (Dew

Table 2. Cysts of larval cestodes of sheep and cattle

Cysts/larval stage	Intermediate hosts	Location	Size	Appearance	Tapeworm, length, location	Definitive host
Hydatid cyst (<i>Echinococcus granulosus</i>)	Sheep, cattle, goat, pig, wallaby, kangaroo, human, deer, camel, wombat.	Liver, lung, kidneys, spleen, heart, brain, bone.	4–5 mm at 3 months; 20 mm at 6 months.	Viable cysts enclosed within laminated fibrous capsule and embedded in substance of affected organ. If fertile, contain many protoscolices ('hydatid sand'). Degenerated cysts contain caseous material that 'shells out'.	<i>Echinococcus granulosus</i> , 4–6 mm (4–6 segments), small intestine.	dog, dingo, fox
Sheep measles (<i>Cysticercus ovis</i>)	Sheep, goat.	Heart, diaphragm, masseter muscles, oesophagus, all striated muscle.	3–6 mm at 7 weeks. Oval shape, up to 10 mm long.	Viable cysts contain fluid and a single protoscolex. Dead cysts become calcified.	<i>Taenia ovis</i> , 2 m, small intestine.	dog
Beef measles (<i>Cysticercus bovis</i>)	Cattle, buffalo, deer, giraffe.	Heart, tongue, masseter muscles, diaphragm, all striated muscle.	Variable in size: 2–20 mm; average 5 mm. Fully developed in 16 weeks.	Viable cysts contain fluid and a single protoscolex. Degenerated cysts become caseous and calcified.	<i>Taenia saginata</i> , 4–10 m, small intestine	human
Bladder worms (<i>Cysticercus tenuicollis</i>)	Sheep, cattle, goat, pig.	Liver, abdominal cavity.	Average 50 mm; range 1–60 mm.	Cysts loosely attached to surface of viscera. Contain clear, jelly-like fluid and a single large protoscolex.	<i>Taenia hydatigena</i> , 3 m, small intestine.	dog, dingo

Note: *Taenia pisiformis*, *T. serialis* and *Dipylidium caninum* are common tapeworms of dogs, foxes and dingoes that need to be differentiated from *T. ovis* and *T. hydatigena*. The intermediate hosts of *T. pisiformis* and *T. serialis* are the rabbit and hare. The flea and possibly the biting louse are the intermediate hosts for *D. caninum*. Modified from Love & Hutchinson 2003, adapted from Cole 1986.

1928). Although human hydatidosis was a notifiable disease in most states until 2001, it was frequently under-reported (Schreuder 1990).

A study of hospital records in New South Wales and the Australian Capital Territory (Jenkins & Power 1996) covering the period 1987–92 found:

- in 15 shires in the north-east, a range of 0.3 to 17.7 cases per 100 000 population;
- in 24 shires in the south-east, a range of 0.5 to 3.5 cases per 100 000 population.

In the 5 year period covered by the study, 321 patients were treated in NSW and ACT hospitals, but only 17 of these cases had been notified. Of these, 195 were new cases and 117 recurrent cases.

The mean annual human prevalence in rural NSW was calculated to be 2.6 cases per 100 000. Four cases were reported in Aboriginal persons (mean annual prevalence of 1.1 cases per 100 000 Aboriginal population of NSW).

The age at which hydatids was found varied depending upon the place of birth. Most Australian-born patients were 31–40 years of age, whereas those born outside Australia were mostly 41–50 years of age. Because the disease appears as a result of the slow growth of the cyst, infection picked up in childhood often does not appear until later. However, there is evidence that a proportion of new infections would have occurred as adults, so no person should consider themselves immune from this disease. An earlier study of the disease in

humans found that the average stay in hospital for hydatid disease patients was 23 days.

Children are the group at greatest risk of hydatid infection because of their close association with dogs and their sometimes casual approach to personal hygiene. Any dog that has had access to fresh offal, including livers from butchers, could be infected with this tapeworm.

Hydatids in humans is a serious disease. With improved diagnostic techniques, in particular computerised axial tomography (CT) and magnetic resonance imaging (MRI), whereby cyst lesions can be more easily identified, the danger of the disease has been reduced. However, the formation of cysts in the body is always dangerous and their surgical removal is never straightforward. A major concern during surgery to remove cysts is that brood capsules can float free within the cyst. If a cyst ruptures, the brood capsules can spread through the body and secondary cysts can grow wherever they come to rest. This contributes to the high level of recurrence (37.5% of patients). Steps taken to sterilise the contents of the cyst during surgery, and post-operative treatment with albendazole, will greatly reduce this risk. Deaths from hydatid disease still occur both before and after surgery.

The real tragedy of hydatid disease is that it happens at all, as the infection can result only from swallowing eggs released from an infected dog, dingo or fox. This is an event that can be prevented by following the simple measures outlined below.

The control of hydatids

The control of hydatids involves ensuring that dogs are not infected with the tapeworm, either by preventing the dog from eating tapeworm heads or by cleaning out any tapeworms infecting it, preferably before they have had a chance to mature. Effective control methods include the following:

1. Feed only manufactured dog foods.

These foods contain materials cooked in such a way that there is no risk of contamination by tapeworm heads in or on the materials used such as liver, lung or meat by-products. Also, the majority of commercial rations have been prepared under the direction of nutritionists specialising in such foods, and so contain all the nutrients essential for a balanced diet.

Feeding unprocessed meats or meat by-products to dogs carries with it the risk that contamination from ruptured cysts may have occurred during the slaughtering process, and, as a result, the dog could become infected. It is very difficult to cook meat at home adequately because of the time

required to thoroughly heat the centre of a piece of meat. Commercial companies use pressure cookers which ensure that adequate temperatures are reached.

2. Prevent access to dead stock or fresh offal.

Access by dogs to dead stock or fresh offal can be from scavenging or by the deliberate feeding of meat, liver, lungs or even blood from the slaughtering process. Hydatid cysts, which can be in the carcase or have contaminated the meat or other material, may be eaten by the dog, causing it to become infected with the tapeworm.

- **Rural dogs.** Dogs should be kept in kennels, in runs or on leads when not working or under supervision. Unsupervised dogs can find carcasses or, worse still, attack and kill lambs, sheep or other small stock. Sheep provide the greatest risk because they have the greatest proportion of viable cysts when infected.
- **Suburban dogs.** Legislation requires that all dogs in public places be under the direct control of a responsible person.

If you know that what your dog eats is safe and you know where your dog goes, you can make sure that no risk of eating tapeworm heads can occur and your dog cannot become infected with the hydatid tapeworm.

3. Wash your hands after handling dogs.

Even though you take every precaution to keep your dog free from hydatids, you cannot be sure of the attention other people give to their dogs.

Before handling food, smoking a cigarette or, in fact, doing anything where your hands could transfer eggs from the dog's coat to your mouth, you should wash your hands thoroughly. Teach your children to do the same, particularly after playing with dogs and before eating.

4. Treat dogs which may have infection.

If dogs have not been fed safe foods or if they have wandered away and there is a risk that they might have eaten hydatid cysts by scavenging, then treatment with a drug that is 100% effective against the hydatid tapeworm should be carried out. The only drug which is this effective at the moment is praziquantel. (There are 86 different registered products contain praziquantel, many of which are 'all-wormers' with activities against other worm types.) This drug is very safe to give to dogs and can be served in their food.

When treating potentially infected dogs, take great care in disposing of the droppings for 2–3 days after treatment. Numerous eggs from dead and dying tapeworms will be present in the droppings.

Dispose of them by deep burial or burning. These eggs pose a health hazard because they are not affected by the treatment.

Where a constant risk of infection occurs, treat the dog every 6 weeks to eliminate tapeworms before they grow to maturity and begin to release eggs.

Eradication programs

As far as human health is concerned, the infectivity of various strains to humans is of primary importance for the development of control programs. Several countries have undertaken programs to either eradicate or control hydatid disease in their human populations, including Iceland, New Zealand and Cyprus, as well as in Tasmania.

Tasmanian program

The Tasmanian program started in 1962 with public meetings and the formation of action committees to create public awareness of the serious health risk being posed by hydatids. In 1960 a survey had shown a human incidence of 92.5 cases per 100 000. A further study in 1963 identified 537 new cases in the decade 1953–62. Also, 60% of sheep carried cysts and about 12% of rural dogs carried the tapeworm.

The program was planned along the lines of the successful New Zealand program but with one important difference. In essence, the program was based on the regular testing of dogs for infection with the tapeworm, combined with an educational program emphasising that preventing dogs from obtaining offal would prevent hydatid infection.

However, the whole test was carried out on the spot rather than having the samples sent to a central laboratory for examination. Later, abattoir monitoring of sheep was introduced to trace properties with infected dogs.

In 1966, the voluntary program became compulsory because a large part of the population favoured the initiative. The success of the program can be measured by the fact that, from its commencement in 1966, the number of new cases in humans fell from 18 per year to 4 per year in 1983. The prevalence of the tapeworm in dogs fell from 12% to 0.04% (1 dog), and the prevalence of hydatid cysts in sheep older than 3 years of age fell from 60% to 0.8%.

Tasmania was favoured in this program because the domestic dog is the only host of the adult tapeworm on the island. There are no dingoes, and so the wildlife (sylvatic) cycle does not occur (recent deliberate introductions of foxes into Tasmania notwithstanding).

By 1996 the last known infected sheep groups had

been slaughtered, and Tasmania declared itself provisionally free from hydatids disease in dogs and sheep (Middleton 2002). If this status is maintained, it is likely that the G2 Tasmanian sheep strain will have been eradicated from its source, although it is still found in Argentina (Kamenetzky et al. 2002).

The difficulty on mainland Australia

On mainland Australia, the dingo, wild dog and, to a very minor extent, the fox provide alternative hosts, and so the dingo–wallaby cycle can continue the infection. This makes the eradication of the tapeworm impossible and the wildlife cycle of increasing importance in human infections, especially in areas bordering National Parks, such as Kosciuszko, where control of wild dogs/dingoes is difficult (Jenkins & Morris 2003, Jenkins & McPherson 2003), and in suburban areas fringing regional towns (Brown & Copeman 2003).

New Zealand program

In New Zealand, *Echinococcus* has been 'reduced to the point of extinction', with the last reported fertile cysts occurring in three sheep on an island in the Marlborough Sound in 1995. The country was declared provisionally free from hydatids disease in 2002 (Pharo 2002).

The cost of the disease in animals

Estimating the cost of the disease in animals is very difficult because of the wide range of animals affected. However, large quantities of edible meat by-products, such as liver and lungs, are downgraded to 'meatmeal' because of the presence of hydatid cysts at slaughter. One estimate of the loss in 1980 from this source put the figure at about \$650 000 annually.

In some lines of sheep, particularly old ewes from the Tablelands, up to 80% may be infected. There has been no estimation of the potential loss from ill-thrift or early culling of sheep and goats. From abattoir reports on the extent of infection with cysts in individual animals, economic loss of this kind could be possible.

Evidence exists that there has been an improvement in the situation in areas where efforts in controlling hydatids are being put into effect. In the majority of areas, hydatid disease can be controlled and the prevalence of the infection reduced by following the recommended methods.

Only in those areas where the infection results solely from contamination of pastures by dingoes will there be little impact on the disease in livestock. However, protection of the family by following the recommendations with regard to dogs is still applicable.

Further information

For further information, contact your local veterinarian or NSW Department of Primary Industries.

Acknowledgments

The author of the first edition (Stuart King, former Senior Field Veterinary Officer) acknowledged the work of the Goulburn and District Hydatid Eradication Committee in the preparation of the hydatid life cycle illustration, and the New Zealand National Hydatids Council and the Tasmanian Hydatid Eradication Council for the material they produced.

Further reading

Brown, B, & Copeman, DB 2003, 'Zoonotic importance of parasites in wild dogs caught in the vicinity of Townsville', *Australian Veterinary Journal*, 81: 700–2.

Cole, VG 1986, *Animal Health in Australia*, Volume 8 'Helminth parasites of sheep and cattle', Department of Primary Industries, Australian Government Publishing Service, Canberra, p. 255.

Dew, HR 1928, *Hydatid disease. Its pathology, diagnosis and treatment*, Australasian Medical Publishing Company Ltd., Sydney, p. 427.

Eckert, J, Gemmell, MA, Meslin, F-X & Pawlowski, ZS (eds) 2001, *WHO/OIE Manual on Echinococcosis in humans and animals: A public health problem of global concern*, World Organisation for Animal Health, Paris, France, p. 265.

Fasihi Harandi, M, Hobbs, RP, Adams, PJ, Mobedi, I, Morgan-Ryan, UM & Thompson, RCA 2002, 'Molecular and morphological characterisation of *Echinococcus granulosus* of human and animal origin in Iran', *Parasitology*, 125: 367–373.

Jenkins, DJ & Macpherson, CNL 2003, 'Transmission ecology of *Echinococcus* in wild-life in Australia and Africa', *Parasitology*, 127: secs 63–72.

Jenkins, DJ & Morris, B 2003, '*Echinococcus granulosus* in wildlife in and around the Kosciuszko National Park, south-eastern Australia', *Australian Veterinary Journal*, 81: 81–85.

Jenkins, DJ & Power, K 1996, 'Human hydatidosis in New South Wales and the Australian Capital Territory, 1987–1992', *Medical Journal of Australia*, 164: 18–21.

Kamenetzky, L, Gutierrez, AM, Canova, SG, Haag, KL, Guarnera, EA, Parra, A, Garcia, GE & Rosenzvit, MC 2002, 'Several strains of *Echinococcus granulosus* infect livestock and

humans in Argentina', *Infection, Genetics and Evolution*, 2: 129–36.

Love, SCJ & Hutchinson, GW 2003, 'Pathology and diagnosis of internal parasites of ruminants' in *Gross Pathology of Ruminants*, Proceedings 350, Post Graduate Foundation in Veterinary Science, University of Sydney, Ch. 16, pp. 309–38.

McCullagh, PJ 1996, 'Hydatid disease: medical problems, veterinary solutions, political obstacles' (editorial), *Medical Journal of Australia*, 164: 7–8.

McManus, DP & Thompson, RCA 2003, 'Molecular epidemiology of cystic echinococcosis', *Parasitology*, 127: secs 37–51.

Middleton, M 2002, 'Provisional eradication of hydatid disease in Tasmania – the final campaign stages', Proceedings, Australian Society for Parasitology, Annual Scientific Meeting, Hobart, p. 19.

Pharo, HJ 2002, 'New Zealand declares provisional freedom from hydatids', Proceedings, Australian Society for Parasitology, Annual Scientific Meeting, Hobart, p. 19.

Schreuder, S. 1990, 'Survey of hospital admissions for hydatidosis in New South Wales and Australian Capital Territory, 1982–1987', *Australian Veterinary Journal*, 67: 149–51

Thompson, RCA & McManus, DP 2002, 'Towards a taxonomic revision of the genus *Echinococcus*', *TRENDS in Parasitology*, 18: 452–7.

© State of New South Wales
through NSW Department of Primary Industries 2007

ISSN 1832-6668

Replaces Agfact A0.9.43

Check for updates of this Primefact at:
www.dpi.nsw.gov.au/primefacts

Disclaimer: The information contained in this publication is based on knowledge and understanding at the time of writing (February 2007). However, because of advances in knowledge, users are reminded of the need to ensure that information upon which they rely is up to date and to check currency of the information with the appropriate officer of New South Wales Department of Primary Industries or the user's independent adviser.

Always read the label

Users of agricultural (or veterinary) chemical products must always read the label and any Permit before using the product, and strictly comply with the directions on the label and the conditions of any Permit. Users are not absolved from compliance with the directions on the label or the conditions of the Permit by reason of any statement made or not made in this publication.

Job number 7383